

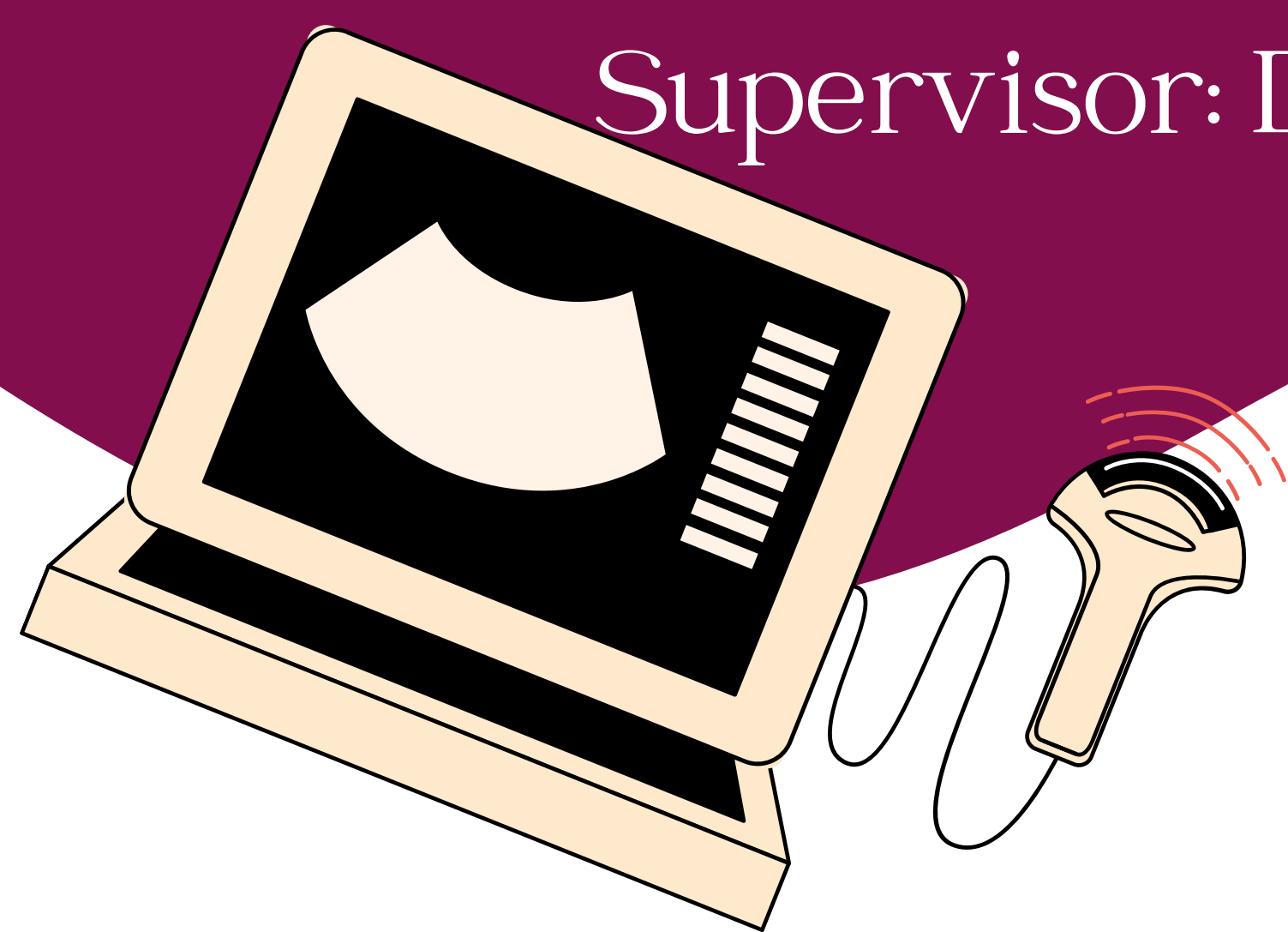
Burjeel Hospital

Obstetrics & Gynecology

Clinical Observership

Shahd Abdelghany

Supervisor: Dr. Sailaja Vuppu

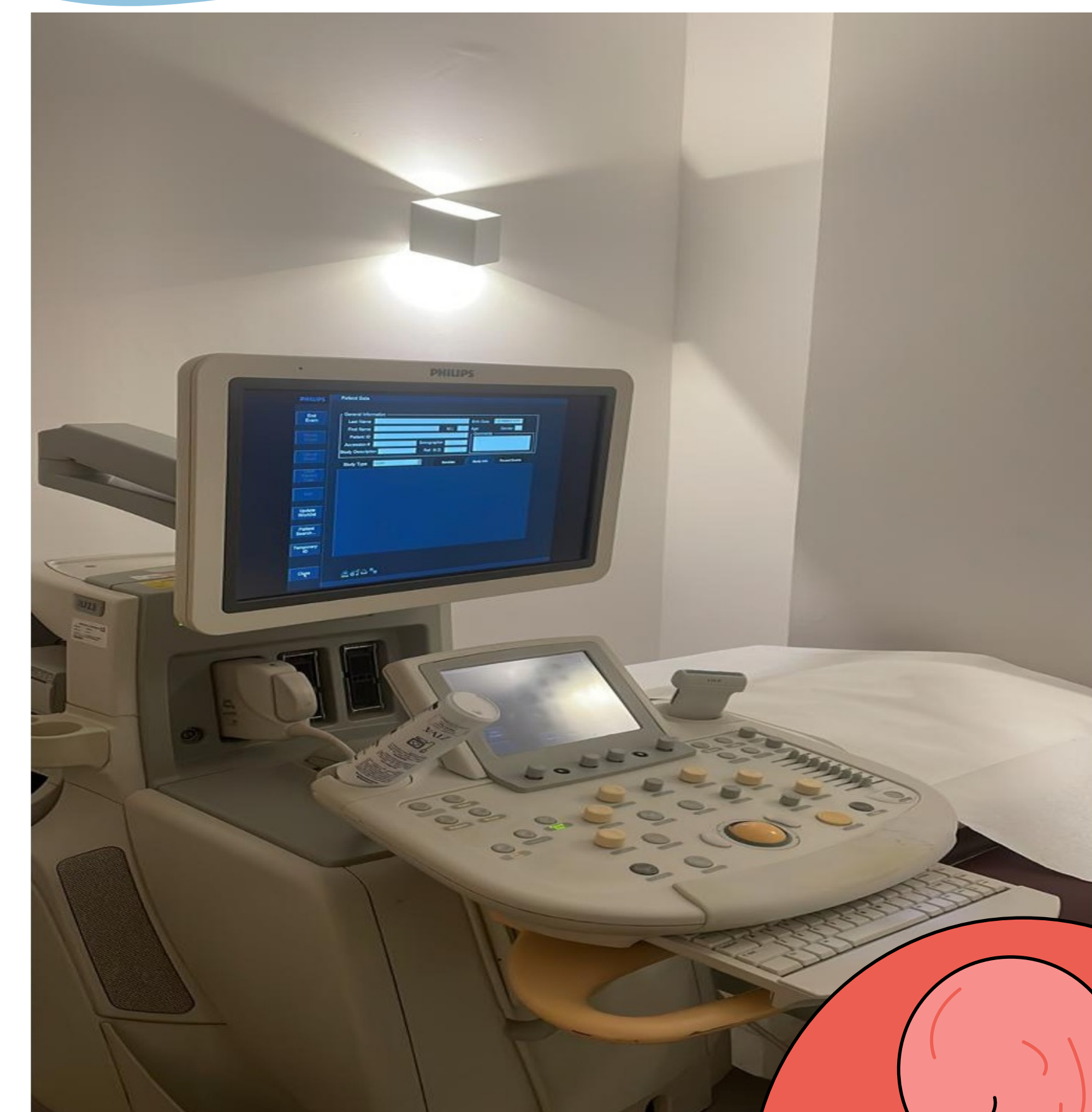

Introduction

My week spent at Burjeel Hospital's obstetrics and gynecology department was an eye-opening experience. I observed diverse cases and learned about patient history gathering and examinations. I was drawn to the variety of care this specialty involves such as labor, surgery, and in-clinic procedures. The highlight of my observership was witnessing many intriguing surgeries in an OR setting, introducing me to new methods and procedures.

Cesarean Scar Defect

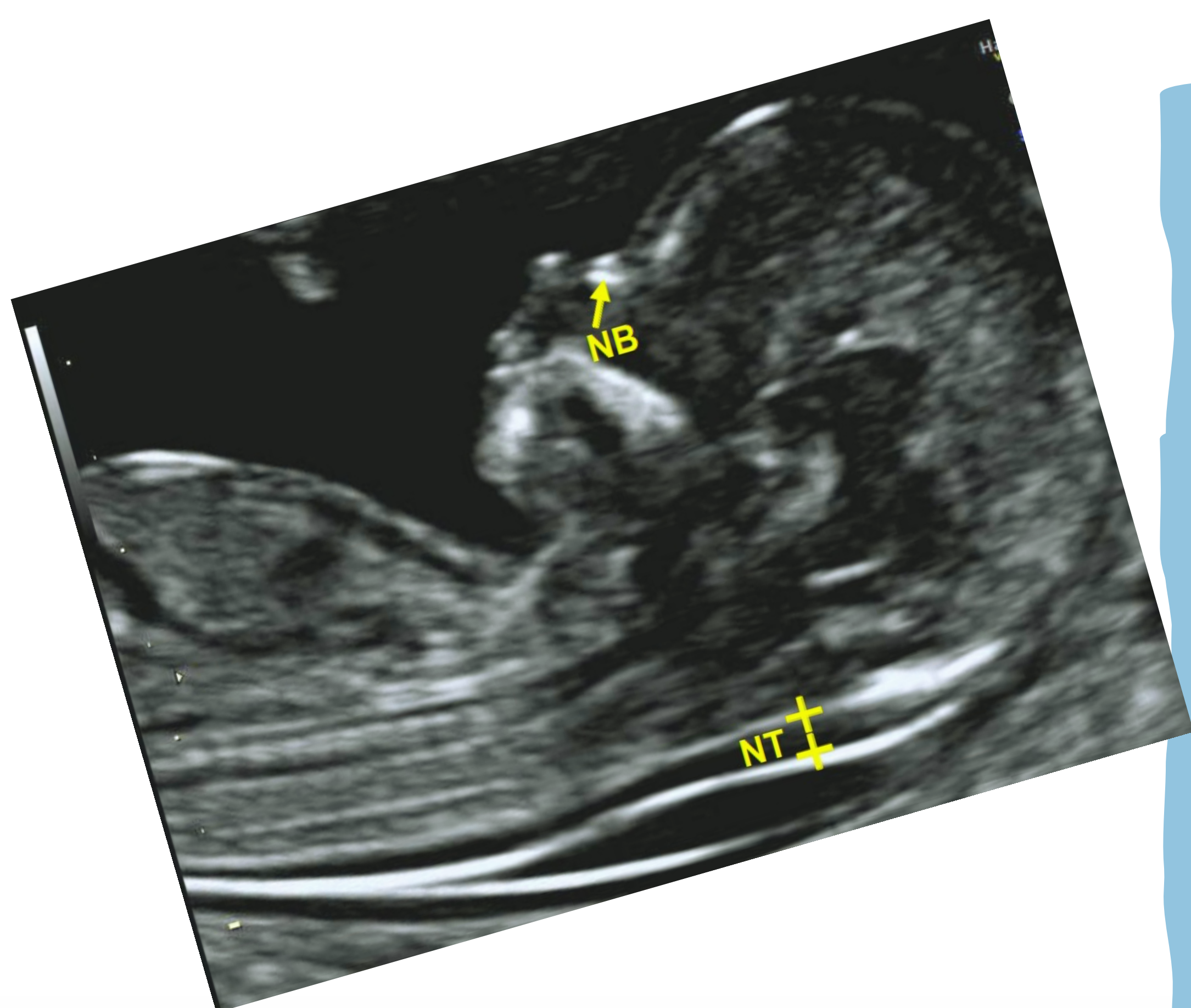
- Also known as a niche or isthmocele
- A pouch that forms in the uterus due to a cesarean incision that hasn't healed completely. This pouch can fill up with blood and cause abnormal uterine bleeding.
- It can be repaired laparoscopically.
 - The niche is first identified hysteroscopically. The light from the hysteroscope can be seen laparoscopically due to the thinned-out myometrium in the area of the defect.
 - The scar tissue is then excised, and the myometrium is sutured.



Fetal Medicine

NT (Nuchal Translucency) Scan:

- An ultrasound that is done between 11-13 weeks of pregnancy
 - used to determine the amount of fluid normally found in the space behind the baby's neck (nuchal fold). This is important as it can help estimate the risk of chromosomal abnormalities such as Down's syndrome. Another marker for Down syndrome on an NT scan includes the absence of the nasal bone.
- Additionally, I got to learn more about anomaly and growth scans which are important when it comes to monitoring a baby's development and growth further into pregnancy.



برجیل
burjeel

a burjeel holdings company